



Chloral Hydrate Overdose Survived after Cardiac Arrest with Excellent Response to Intravenous β -blocker

Shaik Karimulla Shakeer^{1*}, Babji Kalapati¹, Suad Abdullah Al Abri² and Mujahid Al Busaidi¹

¹Department of Anesthesia and ICU, Sultan Qaboos University Hospital, Muscat, Oman

²Department of Emergency Medicine, Sultan Qaboos University Hospital, Muscat, Oman

ARTICLE INFO

Article history:

Received: 20 August 2017

Accepted: 1 April 2018

Online:

DOI 10.5001/omj.2019.46

Keywords:

Chloral Hydrate; Poisoning; Cardiac Arrhythmias; Cardiac Arrest; Central Nervous System Depressants.

ABSTRACT

Chloral hydrate (CH) poisoning is not commonly seen in the emergency department. CH is a commonly prescribed sedative agent for various day care procedures despite its toxic profile even when other safe sedative medications are available. We report a case of CH poisoning that manifested with neurotoxicity followed by cardiotoxicity leading to cardiac arrest. With a high index of suspicion and proper management, our patient was discharged with normal neurological outcome. In this case report, we discuss CH poisoning and toxicity with highlights on specific intervention including β -blockers. CH induced arrhythmias have been reported to be refractory to the standard antiarrhythmic medications and respond well to β -blockers.

Chloral hydrate (CH) is a hydrocarbon historically used as a sedative, hypnotic, and anxiolytic agent mainly in radiological imaging procedures.¹⁻³

Cardiac arrhythmias have been reported even with therapeutic doses of CH with a risk of sudden death,⁴ which made CH less commonly used as sedative agents.⁵

The half-life of CH is 30–60 minutes, but its active metabolite trichloroethanol duration of action lasts for more than eight hours and up to 35 hours at higher doses.^{4,6}

Acute poisoning with CH causes significant central nervous system (CNS) depression, respiratory failure, and tachyarrhythmias. The other reported side effects are gastric irritation and vomiting.^{7,8} The common cause of death due to CH toxicity is cardiac arrhythmia and unrecognized respiratory arrest due to CNS depression.⁷

CH induced cardiac arrhythmias are usually refractory, which are unresponsive to standard antiarrhythmic drugs including amiodarone and lidocaine.^{6,7,9,10} However, β -blockers have been reported to be an effective treatment of hydrocarbon-induced cardiotoxicity, including CH.¹¹⁻¹³

We report a case of CH poisoning with cardiac arrest and complete recovery.

CASE REPORT

A 23-year-old woman, with no significant medical history, was brought to the emergency department after being found unresponsive at home. Her family found medication strips of paracetamol and diclofenac beside her. Her initial vital signs at presentation were as follows: pulse rate of 95 beats per minute; blood pressure of 109/83 mmHg; respiratory rate 25 breaths per minute; and a temperature of 37 °C. Her initial physical exam was unremarkable apart from a low Glasgow coma scale of 7/15 with normal size reactive pupils. Due to her CNS depression, she was intubated and mechanically ventilated. A nasogastric tube was inserted, and gastric lavage was done with pinkish fluid and some particles coming out. Analysis of the contents of gastric lavage was not possible.

Electrocardiogram (ECG) at the time of presentation showed multiple premature ventricular contractions [Figure 1]. ECG repeated 30 minutes later showed prolonged QT interval [Figure 2]. Her arterial blood gas showed metabolic and respiratory acidosis with a pH = 7.16; pO₂ = 82 mmHg; pCO₂ = 53 mmHg; and bicarbonate = 16 mmol/L. The toxicology screening for tricyclic antidepressants, salicylates, benzodiazepines, acetaminophen, morphine, cocaine, marijuana, phencyclidines,

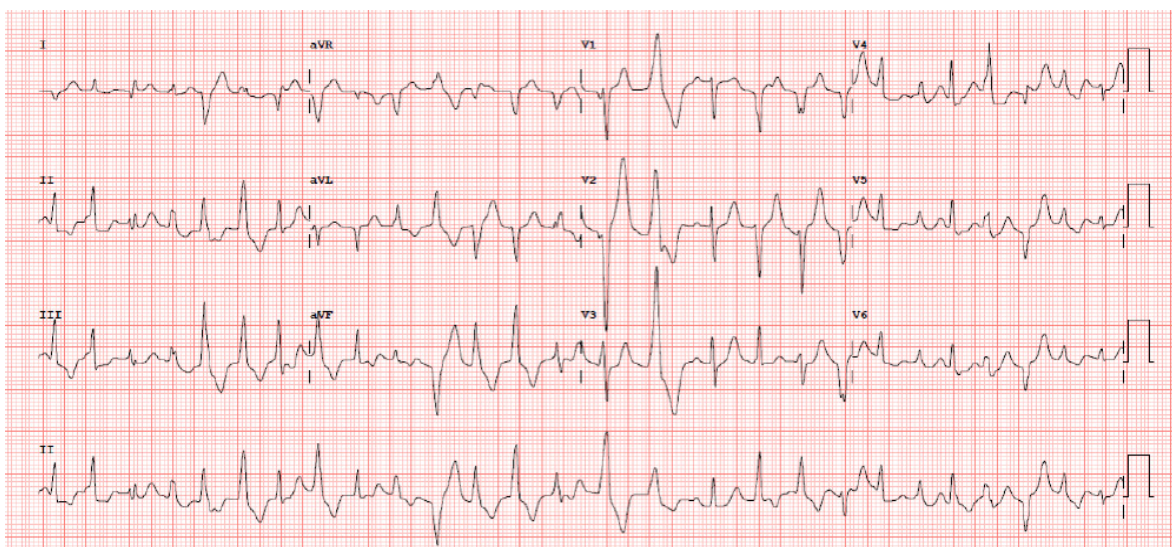


Figure 1: Electrocardiogram at presentation showing multiple premature ventricular contractions.

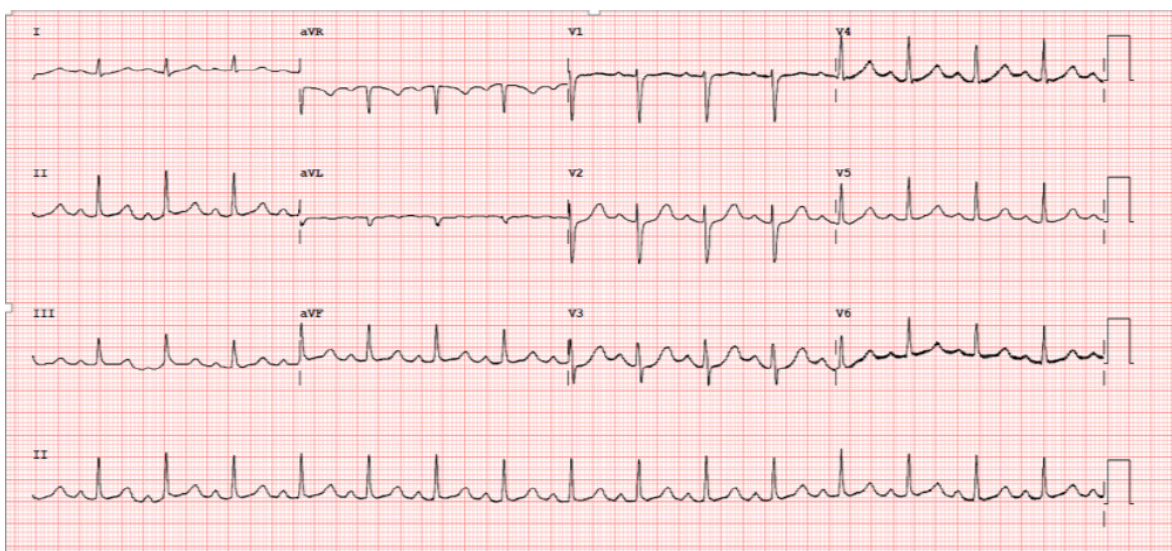


Figure 2: Electrocardiogram performed 30 minutes after presentation shows normal sinus rhythm with a prolonged QT interval.

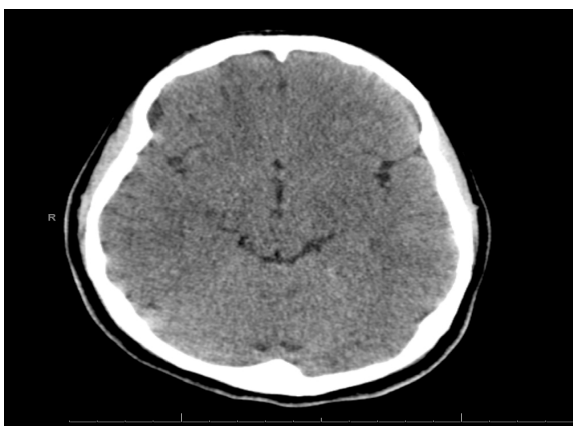

Figure 3: Normal brain computed tomography scan.

amphetamines, methadone, and barbiturates were all negative. Brain computed tomography [Figure 3] and chest radiography were also unremarkable. All her laboratory investigations were normal apart from low bicarbonate (17 mmol/L) and elevated lactate (3.5 mmol/L).

Within nine hours of hospital presentation, she had multiple episodes of ventricular fibrillation (VF) requiring cardiopulmonary resuscitation. Her VF was refractory to the standard advanced cardiac life support protocol including epinephrine, amiodarone, and defibrillations. A clinical toxicologist was consulted, and due to the combination of cardiotoxicity and sedation, hydrocarbon poisoning

was considered. Esmolol (β -blocker) infusion was started with a dose of 150 $\mu\text{g}/\text{kg}/\text{min}$ following an intermittent bolus dose of 30 mg to a total bolus dose of 150 mg, and shortly after, she reverted to sinus rhythm.

She developed hypotension and was supported initially with intravenous fluid resuscitation and norepinephrine infusion, but following her cardiac arrest, it was changed to phenylephrine infusion. Later her sister brought the patient's bag that had a bottle of water with pinkish fluid inside, smelling like CH. There was no toxicological test available for CH confirmation. Over the next 36 hours, the patient's neurological and cardiac status had normalized,

and she was extubated successfully and was weaned from phenylephrine and esmolol infusion. She was discharged from the hospital in good condition on day five after psychiatric review. She confirmed the ingestion of around 30–35 g of CH.

DISCUSSION

This case represents significant lethal ingestion of CH causing cardiac arrest with a favorable outcome. Although the dose considered to be fatal for CH is about 10 g, fatalities have been documented with ingestion of as little as 4 g and the recovery of a patient following ingestion of 30 g CH was

Table 1: Reported cases of chloral hydrate overdose.

Author/year	Age, years	Sex	Presentation	Amount ingested	Treatment
Wong et al, ⁷ 2009	42	F	Chest pain, wide complex tachycardia	20 g	Responded to lidocaine infusion, discharged on day eight.
Wong et al, ⁷ 2009	44	M	Clouded sensorium, wide complex tachycardia with multiple ventricular premature contractions	10 g	Did not respond to amiodarone. Responded to propranolol bolus then labetalol infusion.
Gleich et al, ¹⁴ 1967			Recurrent VT	18 g	Responded to repeated doses of procainamide.
Gustafson et al, ⁹ 1977 (three cases)	39	F	Occasional supraventricular tachycardia, frequent ventricular premature beats	30 g	Did not respond to lidocaine, but responded to phenytoin.
Bowyer et al, ¹⁰ 1980 (two cases)					Responded to propranolol.
Allan et al, ¹⁵ 2001	54	M	Unconscious, cardiac arrest due to VF	Three bottles of chloral hydrate (psychiatric patient)	Responded to defibrillation. Pharmacological therapy not mentioned.
Donovan et al, ¹⁶ 1989	40	M	Unconscious, hypotension	10 g	Responded to flumazenil.
DiGiovanni, ¹¹ 1969			Cardiac arrest	18 g	Did not respond to defibrillation and lidocaine. Responded to propranolol.
Nordt et al, ⁴ 2014	4	F	Unresponsive, cardiac arrest	900 mg (70 mg/kg)	ROSC achieved but remained refractory hypotensive and died.
Nordt et al, ⁴ 2014	3	M	Unresponsive, frequent bigeminy, trigeminy	6000 mg (600 mg/kg)	Responded to esmolol infusion, discharged home.
Nordt et al, ⁴ 2014	15 months	F	Stridorous respiration, desaturation	1200 mg (100 mg/kg)	Received oxygen support with bag valve ventilation, her mental status improved.
Zahedi et al, ¹⁷ 1999	27	M	Unresponsive, hypotensive, frequent runs of VT	20 g	Intubated, responded to propranolol bolus and infusion, discharged home.

F: female; M: male; VT: ventricular tachycardia; VF: ventricular fibrillation; ROSC: return of spontaneous circulation.

also reported.^{1,12} Table 1 shows reported cases of CH overdose.

CH overdose is known to cause tachyarrhythmias.^{18,19} Our patient suffered significant cardiotoxicity ranging from sinus tachycardia, multiple atrial and ventricular ectopics, prolonged QT interval, and eventually VF. CH and its metabolites-induced cardiotoxicity could be explained by many mechanisms. One of the suggested effects is the reduced conduction velocity, which causes conduction defects like atrioventricular and intraventricular conduction delays, which can cause re-entrant arrhythmias.¹⁸ Other suggested effects are increased automaticity of the supraventricular and ventricular pacemaker cells and sensitization of the myocardium to the circulating catecholamine.^{9,20}

CH induced VF in our patient did not respond to standard antiarrhythmic drugs but responded well to β -blockers. CH induced arrhythmias have been reported to be refractory to the standard antiarrhythmic medications.^{9,10} A failure to control CH induced arrhythmias with lidocaine was reported in two out of five patients with CH overdose.⁹ Others have reported partial response with lidocaine.¹⁰

A case series of CH overdose showed that VT control was achieved in more than 80% of patients by β -blockers where other antiarrhythmic drugs had failed.¹² In general, β -blockers use for CH induced refractory arrhythmias has been reported to be effective.^{4,9,11-13,17,21} Esmolol infusion was very effective in controlling our patient's tachyarrhythmias and was reported to be effective in other case reports.^{4,21}

Paracetamol and diclofenac tablets found beside our patient were thought to be the culprit of her symptoms by her family. However, neither could explain her presentation especially with negative paracetamol levels and the presence of significant cardiac toxicity. The combination of CNS depression with refractory arrhythmias made hydrocarbon toxicity likely.

Of note, due to CH toxicity induced hypersensitivity to catecholamines, norepinephrine infusion was changed to phenylephrine, which is a selective α agonist.²² Fortunately, our patient did not develop any hepatotoxicity, which has been reported with CH overdose.²³

Our patient survived a massive ingestion of CH and had an excellent outcome despite serious

cardiotoxicity and cardiac arrest due to prompt recognition and good supportive and specific care.

CONCLUSION

CH toxicity usually presents with CNS depression and cardiac toxicity; hence, emergency physicians should have a high index of suspicion of possible hydrocarbon ingestion with such presentations. CH induced tachyarrhythmias are usually refractory to standard antiarrhythmic medications and usually respond well to β -blocker.

Disclosure

The authors declared no conflict of interest.

REFERENCES

- Gerretsen M, de Groot G, van Heijst AN, Maes RA. Chloral hydrate poisoning: its mechanism and therapy. *Vet Hum Toxicol* 1979;21(Suppl):53-56.
- Binder LS, Leake LA. Chloral hydrate for emergent pediatric procedural sedation: a new look at an old drug. *Am J Emerg Med* 1991 Nov;9(6):530-534.
- Bain KT. Management of chronic insomnia in elderly persons. *Am J Geriatr Pharmacother* 2006 Jun;4(2):168-192.
- Nordt SP, Rangan C, Hardmaslani M, Clark RF, Wendler C, Valente M. Pediatric chloral hydrate poisonings and death following outpatient procedural sedation. *J Med Toxicol* 2014 Jun;10(2):219-222.
- Krauss B, Green SM. Sedation and analgesia for procedures in children. *N Engl J Med* 2000 Mar;342(13):938-945.
- Sing K, Erickson T, Amitai Y, Hryhorczuk D. Chloral hydrate toxicity from oral and intravenous administration. *J Toxicol Clin Toxicol* 1996;34(1):101-106.
- Wong OF, Lam TS, Fung HT. Two cases of chloral hydrate overdose. *Hong Kong J Emerg Med* 2009 Jul;16(3):161-167
- Pershad J, Palmisano P, Nichols M. Chloral hydrate: the good and the bad. *Pediatr Emerg Care* 1999 Dec;15(6):432-435.
- Gustafson A, Svensson SE, Ugander L. Cardiac arrhythmias in chloral hydrate poisoning. *Acta Med Scand* 1977;201(3):227-230.
- Bowyer K, Glasser SP. Chloral hydrate overdose and cardiac arrhythmias. *Chest* 1980 Feb;77(2):232-235.
- DiGiovanni AJ. Reversal of chloral hydrate-associated cardiac arrhythmia by a beta-adrenergic blocking agent. *Anesthesiology* 1969 Jul;31(1):93-97.
- Graham SR, Day RO, Lee R, Fulde GW. Overdose with chloral hydrate: a pharmacological and therapeutic review. *Med J Aust* 1988 Dec;149(11-12):686-688.
- Brown AM, Cade JF. Cardiac arrhythmias after chloral hydrate overdose. *Med J Aust* 1980 Jan;1(1):28-29.
- Gleich GJ, Mongan ES, Vaules DW. Esophageal stricture following chloral hydrate poisoning. *JAMA* 1967 Jul;201(4):266-267.
- Frankland A, Robinson MJ. Fatal chloral hydrate overdoses: unnecessary tragedies. *Can J Psychiatry* 2001 Oct;46(8):763-764.
- Donovan KL, Fisher DJ. Reversal of chloral hydrate overdose with flumazenil. *BMJ* 1989 May;298(6682):1253.
- Zahedi A, Grant MH, Wong DT. Successful treatment of chloral hydrate cardiac toxicity with propranolol. *Am J*

- Emerg Med 1999 Sep;17(5):490-491.
18. Jiao Z, De Jesús VR, Iravani S, Campbell DP, Xu J, Vitali JA, et al. A possible mechanism of halocarbon-induced cardiac sensitization arrhythmias. *J Mol Cell Cardiol* 2006 Oct;41(4):698-705.
 19. Hirsch IA, Zauder HL. Chloral hydrate: a potential cause of arrhythmias. *Anesth Analg* 1986 Jun;65(6):691-692.
 20. Marshall AJ. Cardiac arrhythmias caused by chloral hydrate. *Br Med J* 1977 Oct;2(6093):994.
 21. Marx JA, Hockberger RS, Walls RM. Rosen's emergency medicine. 8th edition. Philadelphia: Elsevier Saunders; 2014.
 22. Berthelsen S, Pettinger WA. A functional basis for classification of α -adrenergic receptors. *Life Sci* 1977 Sep;21(5):595-606.
 23. Ramdhan DH, Kamijima M, Yamada N, Ito Y, Yanagiba Y, Nakamura D, et al. Molecular mechanism of trichloroethylene-induced hepatotoxicity mediated by CYP2E1. *Toxicol Appl Pharmacol* 2008 Sep;231(3):300-307.